

Original article:

A study on functional outcome of Thoraco lumbar vertebra fracture treated with posterolateral instrumental fusion

Dr. Monika Verma , Dr. Tejas Tathe*

Department of Orthopaedics of M.G.M Medical College and Hospital; Aurangabad, India

Corresponding author *

Abstract

Background: The spinal injuries are common problems encountered by an orthopaedician in day to day practice. The data on clinical outcome after instrumented spinal fusion is scant. Hence this study was undertaken to study the clinical outcome of the instrumented spinal fusion.

Material and Methods: A prospective interventional study was undertaken among adult patients with acute thoracolumbar injuries admitted to the tertiary care hospital were included. Fifty adult patients with acute thoracolumbar injuries underwent the fusion with pedicle screws and rod instrumentation (Tango RS, Fa. Ulrich, Germany) with posterolateral fusion. The patients were followed up at 6th, 12th and 24th post operative weeks.

Results: The mean age was 40.1 years and more than three fourth were males. Fall from height was the major cause for the injury. The decrease in regional angle was statistically significant at 6th, 12th and 24th follow up visits when compared to baseline. The anterior wedge angle decreased to 5.24⁰, 5.8⁰ and 5.72⁰ at 6th, 12th and 24th post operative weeks respectively which was statistically significant when compared with the baseline. About 44%, 48% and 54% of the patients had normal sensory and motor functions at 6th, 12th and 24th weeks of follow up after surgery which was statistically significant when compared to the base line.

Conclusion: This study was able to show that the postero lateral fusion had good clinical outcome.

Key words: thoracolumbar injuries, posterolateral instrumental fusion, regional angle, anterior wedge angle

INTRODUCTION

The spinal traumas are leading problem in orthopaedic practice.¹ The thoracolumbar fractures are serious injuries of concern with a marked morbidity and disability if left untreated to the patient. The thoraco- lumbar spine fractures are reported to be around 6% of the trauma patients out of which 2.6% patients sustains spinal cord or nerve root level neurological injury. The thoracolumbar fracture is also associated with the dysfunction of important neurological functions including bowel and bladder disturbances.² The main goal of treatment of spinal injury is restoration of the patient to maximum possible function with disability free life. The treatment focus is on protecting the uninjured neural tissues, maximizing the recovery of the injured neural tissues and optimizing conditions for the musculoskeletal portions of the spinal column to heal in a satisfactory position.

The posterior approach is safe alternative for the surgery as most of the specialists are more experienced.³

The postero- lateral fusion has emerged as a standard procedure in the treatment of the acute traumatic vertebral body fractures of the thoraco- lumbar vertebra. The fusion of the spine helps in treating the instability and

deformity. The fusion promotes the biological stabilization of the fracture and protects the fixation system from material fatigue.⁴ The data on clinical outcome after instrumented spinal fusion is scant. Hence this study was undertaken to study the clinical outcome of the instrumented spinal fusion.

MATERIAL AND METHODS

A prospective interventional study was undertaken in the Department of Orthopaedics in M.G.M Medical college and Hospital, from August 2020 to March 2022. Adult patients with acute thoracolumbar injuries admitted to the tertiary care hospital were included in this study after obtaining the informed, written and video consent. Clearance from institutional ethics committee was obtained. Fifty adult patients with acute thoracolumbar injuries who were undergoing surgery admitted to the hospital constituted the study sample.

A detailed evaluation of the mode of trauma, Frankel grading, sensory level and to check for any spinal deformity was conducted. The patients were clinically evaluated for ensuring the thoracolumbar fracture. Plain X – ray in antero posterior and lateral views were obtained and the instability of the spine was confirmed using White and Punjabi criteria of spinal instability. MRI / CT scan examination was conducted to evaluate the relationships and instability of spine. All the patients underwent the fusion with pedicle screws and rod instrumentation (Tango RS, Fa. Ulrich, Germany) with postero lateral fusion. Endobone and autologous bone obtained from the decompression procedure was used as bone graft. The patients were mobilized as early as possible after the operation procedure with bracing for 12 weeks on the first post operative day. The patients were followed up at 6th, 12th and 24th post operative weeks. The data thus obtained was entered in a pre-designed proforma and entered in to the excel sheet. The data was analysed using Statistical Package for Social Sciences (SPSS vs 20). Independent Sample t test for Quantitative variables, Paired t test for paired observations and Chi – Square test for categorical observations were used as test of significance. Value of less than 0.05 was considered significance level and all the values below it was considered as statistically significant.

Figure 1 preoperative xrays

Figure 2 postoperative xrays Immediate and follow up.

Figure 3 Instruments

Figure 4 clinical pictures of patients in follow up.

RESULTS

Table 1. Socio demographic characteristics of study group

The mean (\pm SD) age of the study group was 40.1 (\pm 11.5) years. More than three fourth of the study subjects were males. Fall from height was the major cause for the injury in this study. More than half of the cases had injury in thoracic vertebra and majority of the fractures were Type A fractures. Steroids were administered in 64% of the study subjects. The mean duration of the injury was 2.68 days and duration of injury to the surgery was 5.62 days. The duration of stay in the hospital was 30.8 days.

Table 2. Regional angle at various follow up visits

The mean regional angle before the surgery was 16.68⁰. After the surgery the mean regional angle decreased to 4.64⁰ at 6th post operative week, 4.9⁰ at 12th post operative week and 4.8⁰ at 24th post operative week. The decreases in regional angle was statistically significant at 6th, 12th and 24th follow up visits when compared to baseline.

Table 3. Anterior wedge angle at various follow up visits

The mean anterior wedge angle was 19.06° during pre operative period. The anterior wedge angle decreased to 5.24° , 5.8° and 5.72° at 6th, 12th and 24th post operative weeks respectively which was statistically significant when compared with the baseline.

Table 4. Frankel’s grade at various follow up visits

Pre – operative – 6th Post op week: χ^2 value= 23.799 Pre – operative – 12th Post op week: χ^2 value= 24.796 Pre – operative – 24th Post op week: χ^2 value= 32.9
 df=4 p value= 0.000, Sig df=4 p value= 0.000, Sig df=4 p value= 0.000, Sig

The Frankel’s grading was grade E in 10% of the patients before Surgery. About 40%, 32% and 32% of the patients had absent motor or sensory functions at 6th, 12th and 24th week of follow up. About 44%, 48% and 54% of the patients had normal sensory and motor functions at 6th, 12th and 24th weeks of follow up after surgery which was statistically significant when compared to the base line.

Table no 1 Socio demographic characteristics of study group

| | | Frequency | Percentage |
|-------------------------|-------------------------------|--------------------|------------|
| Age | Age (Mean ± SD) | 40.1 (± 11.5) | |
| Sex | Male | 38 | 76 |
| | Female | 12 | 24 |
| Mode of Injury | Fall from height | 30 | 60 |
| | RTA | 20 | 40 |
| Vertebra | L1-L4 | 24 | 48 |
| | T9- T12 | 26 | 52 |
| Type of Fracture | A | 28 | 56 |
| | B | 15 | 30 |
| | C | 7 | |
| Steroids | Administered | 32 | 64 |
| | Not administered | 18 | 36 |
| | Duration of Injury | 2.68(± 1.3) | |
| | Duration of injury to surgery | 5.62(±1.41) | |
| | Duration of stay | 30.8(±6.5) | |

Table 2 Regional angle at various follow up visits

| Regional angle in degree | Mean | SD | t value vs pre op | p value, Sig vs pre op |
|--------------------------------------|-------|------|-------------------|------------------------|
| Pre-Operative | 16.68 | 4.84 | | |
| 6 th Post-operative week | 4.64 | 3.99 | 17.08 | 0.000, Sig |
| 12 th Post-operative week | 4.9 | 4.07 | 16.19 | 0.000, Sig |
| 24 th Post-operative week | 4.8 | 4.07 | 16.088 | 0.000, Sig |

Table 3. Anterior wedge angle at various follow up visits

| Anterior wedge angle | Mean | SD | t value vs pre op | p value, Sig vs pre op |
|--------------------------------------|-------|------|-------------------|------------------------|
| Pre-Operative | 19.06 | 9.3 | | |
| 6 th Post-operative week | 5.24 | 4.45 | 14.0 | 0.000, sig |
| 12 th Post-operative week | 5.8 | 4.46 | 12.775 | 0.000, sig |
| 24 th Post-operative week | 5.72 | 4.48 | 12.804 | 0.000, sig |

Table 4 Frankel's grade at various follow up visits

| Frankel's grade | Pre-Operative n (%) | 6 th Post-operative week n (%) | 12 th Post-operative week n (%) | 24 th Post-operative week n (%) |
|-----------------|---------------------|---|--|--|
| A | 22 (44.0) | 20 (40.0) | 16 (32.0) | 16 (32.0) |
| B | 1 (2.0) | 3 (6.0) | 4 (8.0) | 4 (8.0) |

| | | | | |
|----------|------------------|------------------|------------------|------------------|
| C | 7 (14.0) | 0 | 3 (6.0) | 2 (4.0) |
| D | 15 (30.0) | 5 (10.0) | 3 (6.0) | 1 (2.0) |
| E | 5 (10.0) | 22 (44.0) | 24 (48.0) | 27 (54.0) |

Figure 1 Pre-operative X-ray

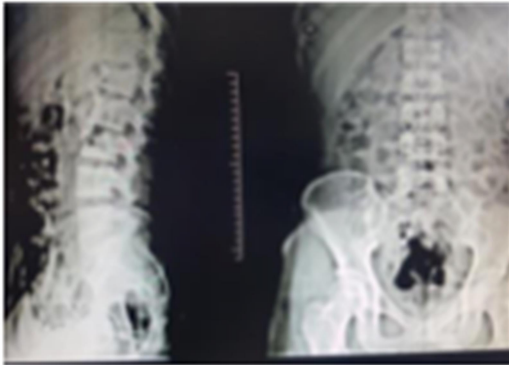
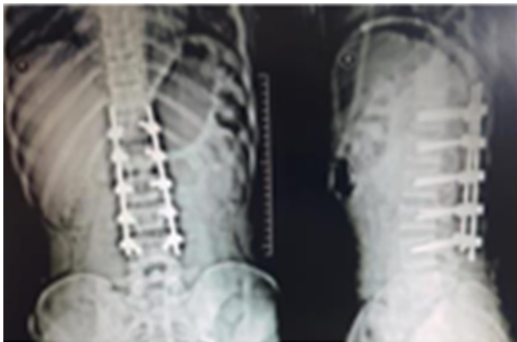
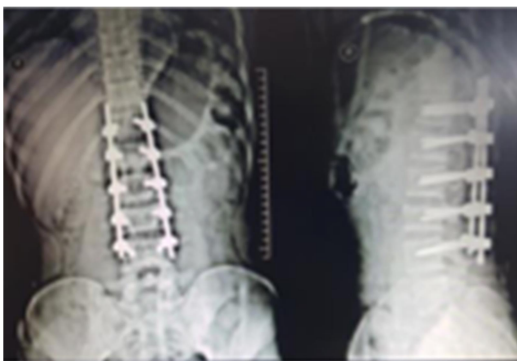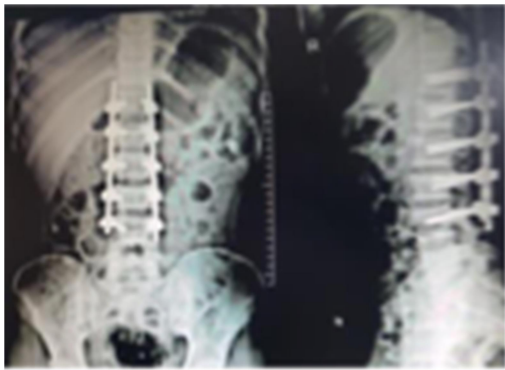
Figure 2 Post-operative X-ray. Immediate post-operative xray



1st follow up xray



2nd follow up xray



3rd follow up xray

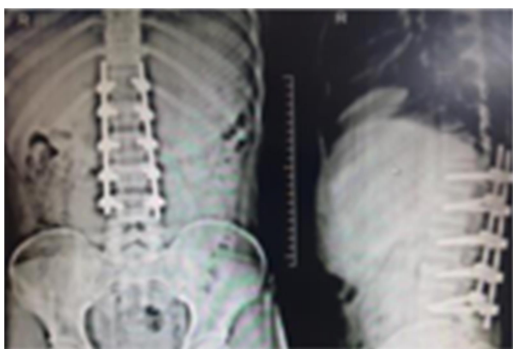


Fig 3 Instruments

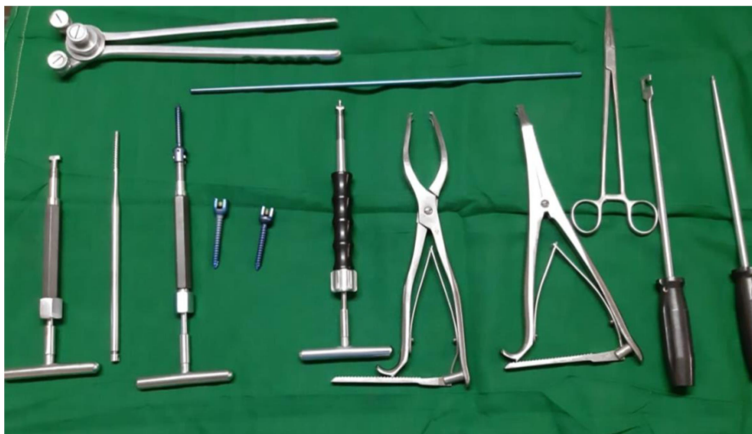
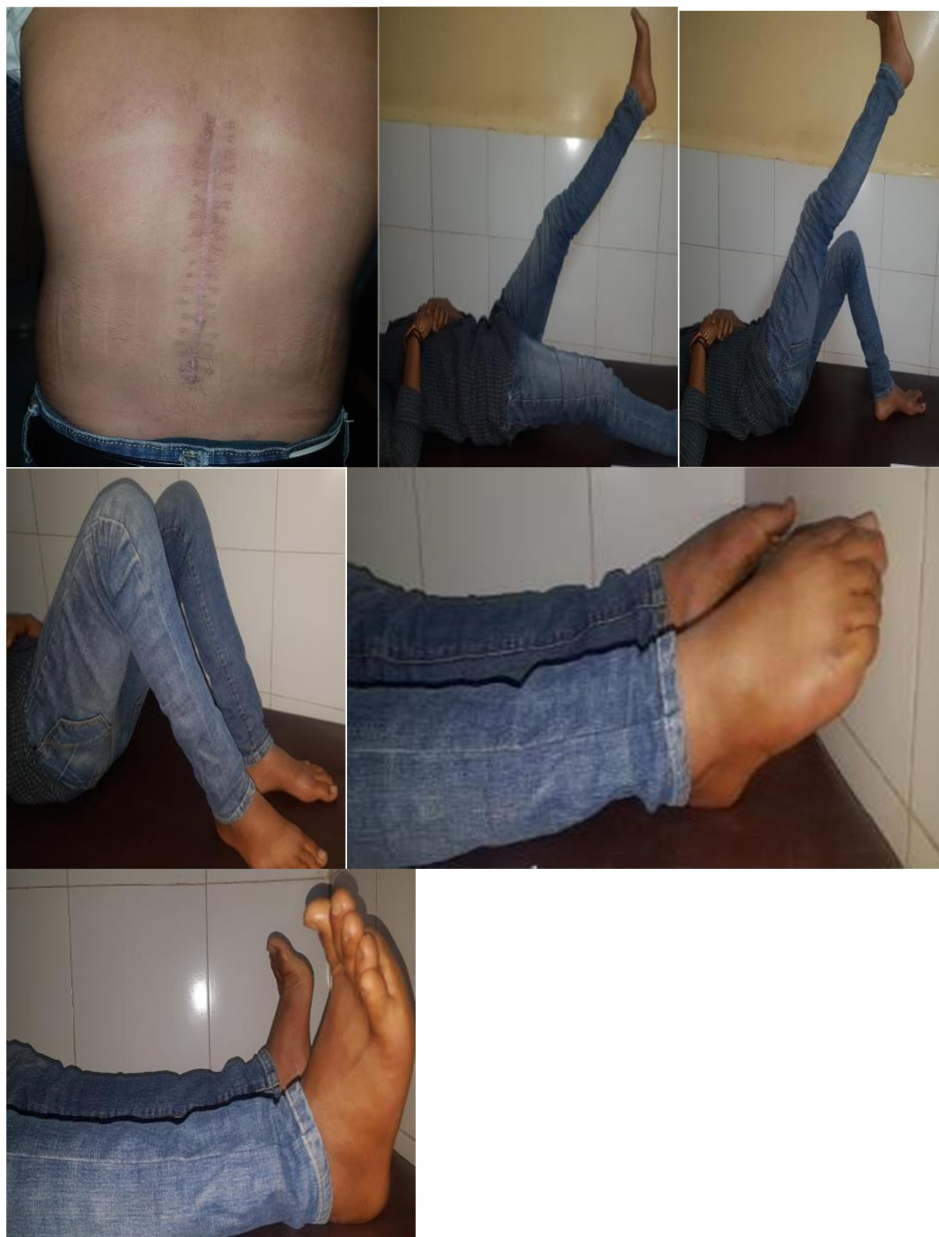
Figure 4 clinical pictures



Discussion

This study was mainly undertaken to study the clinical outcome of the postero-lateral instrument fusion of the thoraco-lumbar vertebra. The literature available has shown a number of surgical procedures depending on the severity and the extent of the spinal stenosis and instability. It varies from laminectomy to wide central laminectomy alone to an anterior release with posterior decompression and fusion with instrumentation. The complications also vary from one procedure to the other procedure.⁵ The rate complications vary from 8 to 80% with the different surgeries of the thoraco- lumbar vertebra fracture.⁶

This study has demonstrated the change in the regional angle, anterior wedge angle and also improvement in function as evident by using Frankel's grading. A study by Bridwell had shown that the

radiographic and functional outcome in patients with decompression and instrumental fusion.⁷ Another study had shown that, the fusion rates among the patients treated with pedicle screw fixation had shown significantly higher rates of fusion. The decompression with PLF and decompression with PLF supplemented with pedicle screw fixation groups had significant improvements in the VAS scores for back and leg pain and reported outcome was good or excellent.⁸

A study by Baumann et al had a fusion rate of 94% in patients undergoing PLF with use of DBM and 100% with the use of ABG.⁹ Andersen et al have reported superior outcomes among the patients with instrumented lumbar spinal fusion. But the study had also revealed that instrumentation was associated with additional surgeries resulting in lesser degree of improvement.¹⁰ The postero- lateral fusion techniques are sometimes challenging for achieving the adequate improvement in sagittal spinal balance of the lumbar spine which influences the clinical outcome over time which is a persistent cause for low back pain. The main limitation of this study was shorter duration of follow up. But long term results of this procedure are awaited. The evaluation of clinical outcome of the surgery requires CT scan. But due to higher radiation ethical issues restrict the follow up.

Conclusion

This study was able to show that the postero lateral fusion had good clinical outcome. The complication rates were less including the intraoperative blood loss and need for transfusions.

References

1. Jens R. Chapman Sohail K Mirza H. Rockwood, Green Fractures in Adults. Lippincott Williams and Wilkins, 5th edition; Vol. 2: 1295 – 1466.
2. Burney RE, Maio RF, Maynard F. Incidence, characteristics, and outcome of spinal cord injury at trauma centres in North America. Arch Surg 1993; 128(5):596-9.
3. Robert W. Bucholz, James D. Heckman: “Rockwood and Greens Fractures in adults”; Lippincott Williams and Willkins; 5th edition; Vol 2; 1293-1466, 2001.
4. Verlaan, JJ, Diekerhof CH, Buskens E, Van Der Tweel I, Verbout AJ, Dhert WJ, Oner FC, Surgical treatment of traumatic fractures of the thoracic and lumbar spine: a systematic review of the literature on techniques, complications, and outcome. Spine, 2004; 29: 803–814.
5. Endres S. Instrumented posterolateral fusion – clinical and functional outcome in elderly patients. GMS German Medical Science. 2011;9:Doc09.
6. Aebi M. The adult scoliosis. Eur Spine J. 2005;14(10):925–948.
7. Bridwell KH, Sedgewick TA, O'Brien MF, Lenke LG, Baldus C. The role of fusion and instrumentation in the treatment of degenerative spondylolisthesis with spinal stenosis. J Spinal Disord. 1993;6(6):461–472.
8. Fischgrund JS, Mackay M, Herkowitz HN, Brower R, Montgomery DM, Kurz LT. 1997 Volvo Award winner in clinical studies. Degenerative lumbar spondylolisthesis with spinal stenosis: a prospective, randomized study comparing decompressive laminectomy and arthrodesis with and without spinal instrumentation. Spine. 1997;22(24):2807–2812.

9. Baumann F, Krustch W, Pfeifer C, Neumann C, Nerlich M, Loibil M, Posterolateral fusion in acute traumatic thoraco lumbar fracture: A comparison of demineralised Bone matrix and Autologus bone graft, *Acta Chir Orthop Traumatol Cech*: 2015; 82: 2: 119 – 25
10. Andersen T, Christensen FB, Niedermann B, Helmig P, Høy K, Hansen ES, Bünger C. Impact of instrumentation in lumbar spinal fusion in elderly patients: 71 patients followed for 2-7 years. *Acta Orthop*. 2009;80(4):445–450.