

“Case Report: Additional insertion of brachialis muscle on the radius bone observed during routine dissection at K.J. Somaiya Medical College , Mumbai.”

Dr. Sharadkumar Pralhad Sawant¹, Dr. Shaguphta T. Shaikh², Dr. Rakhi M. More³

^{1,2,3}Department of Anatomy, K. J. Somaiya Medical College,

Eastern Express Highway, Sion, Mumbai-400 022.

Corresponding author : Dr.Sharadkumar Sawant E-mail: dr.sharadsawant@yahoo.com

ABSTRACT:

During routine dissection for first M.B.B.S. students on 65 years donated embalmed male cadaver in the Department of Anatomy, K. J. Somaiya Medical College, we observed an additional insertion of left brachialis muscle. The origin of the accessory muscle belly was from the anteromedial surface of the shaft and the medial supracondylar ridge of the lower end of the humerus. The accessory muscle slip merged with the tendon of pronator teres and got inserted on to the upper one third of the lateral surface of the shaft of the radius. The accessory muscle belly of the brachialis muscle was innervated by musculocutaneous nerve. There were no associated altered anatomy of the blood vessels observed in the specimen. The right upper limb of the same cadaver was normal. The photographs of the variations were taken for proper documentation and for ready reference. The knowledge of such type of variation is clinically important for Anatomists, Neurologists, Radiologists, Surgeons Plastic surgeons and Orthopedicians.

Key words: Accessory Brachialis Muscle, Median Nerve, Brachial Artery, Variation, Nerve Compression

Introduction:

The brachialis is a muscle in the upper arm that flexes the elbow joint. Its origin extends below to within 2.5 cm of the margin of the articular surface of the humerus at the elbow joint. It also arises from the intermuscular septa of the arm, but more extensively from the medial than the lateral; it is separated from the lateral below by the brachioradialis and extensor carpi radialis longus muscles. Its fibers converge to a thick tendon, which is inserted into the tuberosity of the ulna and the rough depression on the anterior surface of the coronoid process of the ulna. The divide between the two innervations is at the insertion of the deltoid. Unlike the biceps, the brachialis does not insert on the radius, and therefore cannot participate in pronation and supination of the forearm. It flexes the elbow joint. The muscle is occasionally doubled; additional nip to the supinator, pronator teres, biceps brachii, bicipital aponeurosis, brachioradialis or radius are more rarely found (1).

Case Report: During routine dissection for first M.B.B.S. students on 65 years donated embalmed male cadaver in the Department of Anatomy, K. J. Somaiya Medical College, we observed an additional insertion of left brachialis muscle. The origin of the accessory muscle belly was from the anteromedial surface of the shaft and the medial supracondylar ridge of the lower end of the humerus. The accessory muscle slip merged with the tendon of pronator teres and got inserted on to the upper one third of the lateral surface of the shaft of the radius. The accessory muscle belly of the brachialis muscle was innervated by musculocutaneous nerve. The median nerve and the brachial artery travelled deep to the accessory muscle belly of the brachialis muscle. The role of accessory muscles in compression syndrome is a well known phenomenon. Similar to the biceps brachii muscle, the brachialis got inserted on the radius bone, and therefore can participate in pronation and supination of the forearm. There were no associated altered anatomy of the blood vessels observed in

the specimen. The right upper limb of the same cadaver was normal. The photographs of the variations were taken for proper documentation and for ready reference.

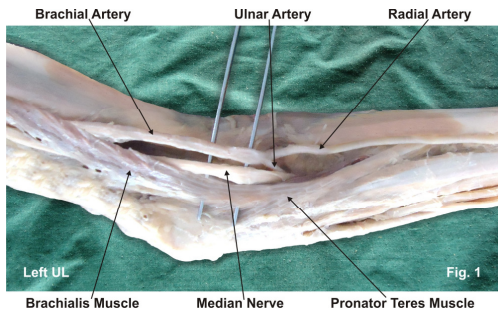


Fig. 1 : The origin of the accessory muscle belly was from the anteromedial surface of the shaft and the medial supracondylar ridge of the lower end of the humerus.

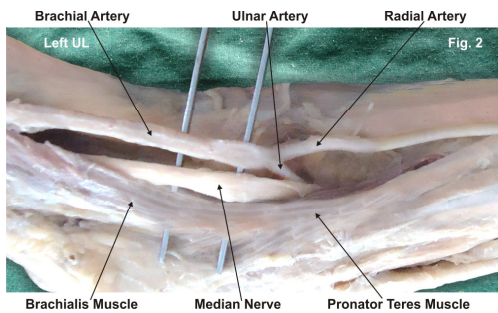


Fig. 2 : The accessory muscle slip merged with the tendon of pronator teres and got inserted on to the upper one third of the lateral surface of the shaft of the radius.

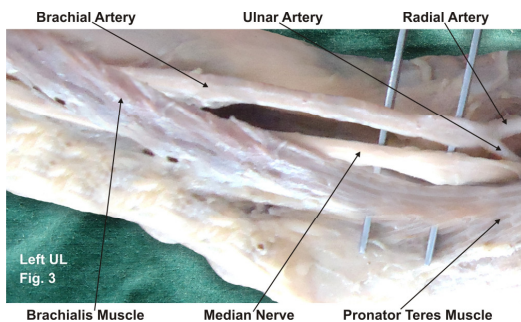


Fig. 3 : The median nerve and the brachial artery travelled deep to the accessory muscle belly of the brachialis muscle.

Discussion: Dharap observed an unusual muscle that passed obliquely from the middle of the humerus anterior to the median nerve and brachial artery, forming a tunnel for them, before inserting with the common origin of the forearm flexor muscles (2). Loukas et al. reported an accessory brachialis muscle originating from mid shaft of humerus and medial intermuscular septum. During its course medially, toward the elbow, the accessory brachialis muscle crossed both the brachial artery and the median nerve. The distal tendon split to surround the median nerve before inserting into the brachialis tendon and the common tendon of the antebrachial flexor compartment muscles (3). Paraskevas et al. have described a variant muscle on the left side arising from the medial border of brachialis muscle and after bridging the median nerve, the brachial artery and vein; it was fused with the medial intermuscular septum. The muscle was innervated by musculocutaneous nerve (4). George and Nayak have described few fleshy fibers of brachialis arising from the distal third of the muscle and merging with superficial flexors of the forearm and to the medial aspect of olecranon process of ulna (5). Rajanigandha et al. reported the occurrence of an accessory brachialis muscle that formed a fibro-muscular tunnel after blending with the medial intermuscular septum (6). Although the accessory brachialis muscle documented in the present case causes no symptoms most of the time but they have the potential to compress the median nerve and the brachial artery with consequent functional impairment. The compression of the median nerve and brachial artery by various types of structures leading to clinical neurovasculopathy has been reported in literature (7,8)

Conclusion: The existence of such variation of the brachialis muscle should be kept in mind by the surgeons operating on patients with high median nerve palsy and brachial artery compression, by the orthopaedicians dealing with fracture of the humerus, the radiologists while doing radiodiagnostic

procedures e.g. CT scan, MRI of the arm and angiographic studies and also by the physiotherapists.

Acknowledgement: All the authors wish to convey our sincere thanks to Dr. Arif A. Faruqi for his valuable help, support and inspiration.

References:

1. Standring S, ed. Gray's Anatomy, The anatomical basis of clinical practice. 39th Ed., Elsevier Churchill Livingstone. 2005; 855.
2. Dharap AS. An anomalous muscle in the distal half of the arm. *Surg Radiol Anat.* 1994; 16: 97–99.
3. Loukas M, Louis RG Jr, South G, Alsheik E, Christopherson C. A case of an accessory brachialis muscle. *Clin Anat.* 2006; 19: 550–553.
4. Paraskevas G, Natsis K, Loannidis O, Papaziogas B, Kitsoulis P, Spanidou S. Accessory muscles in the lower part of the anterior compartment of the arm that may entrap neurovascular elements. *Clin Anat.* 2008; 21: 246–251.
5. George BM, Nayak SB. Median nerve and brachial artery entrapment in the abnormal brachialis muscle – a case report. *Neuroanatomy.* 2008; 7: 41–42.
6. Vadgaonkar R, Rai R, Ranade AV, Nayak SR, Pai MM, Lakshmi R. A case report on accessory brachialis muscle. *Rom J Morphol Embryol.* 2008; 49: 581–583.
7. Gessini L, Jandolo B, Pietrangeli A. Entrapment neuropathies of the median nerve at and above the elbow. *Surg Neurol.* 1983; 19: 112–116.

Source of support: Nil; Conflict of Interest: Nil

Date of submission: 12 Oct 2012

Date of Provisional Acceptance: 24 Oct 2012

Date of Peer review approval: 28 Nov 2012

Date of final drafting: 29 November 2012

Date of Publication: 2 December 2012