

Case Report:

Intramuscular Haemangioma of triceps muscle

**¹Dr Tridib Kumar Sett* , ² Miss Triparna sett , ³Dr Soumedhik De , ⁴Dr Arpan De ,
⁵ Dr Arnab bhar ,⁶Dr Debjyuti Basu**

¹Associate Professor, Anatomy, Malda Medical College, Malda , West Bengal , India

² 2nd yr student, MSC Environmental science, BHU, for preparation of scripts

³ Demonstrator, Anatomy, National Medical College, Kolkata , West Bengal , India

^{4,5,6}. Assistant Professor, Anatomy, Malda Medical College , Malda, West Bengal, India

*Correspondence: e mail address:tridibsett@rediffmail.com

Abstract:

A 14 years boy presented with a swelling in the left elbow on his back measuring 6cm X 4cm X 3cm extending from tip of elbow to axilla on his back, with pain and restriction of movements. Range of motion is flexion 90 degree to 150 degree, supination pronation okay; with a mild history of trauma (? trauma) at his child hood and it is very slowly increasing. On examination, it is doughy feeling, no definite mass is felt. On raising the arm above heart it does not reduce. There is a vague history of trauma at the age of 6 years. Blood parameters are normal. X-ray revealed that in the vicinity of soft tissue swellings there are multiple pearl like swellings starting from 5mm to 8mm around the elbow. Sonogram guided study showed it may be haematoma. CT scan study was same as X rays. On incision, sprouting of blood through the intramuscular tissue of triceps muscles. No involvement of ulnar nerve or periosteal or bone and synovia or joint. Histopathology revealed intramuscular haemangioma

Key words : Triceps , Intramuscular Haemangioma

INTRODUCTION:

Intramuscular Haemangioma are rare entity. Only In Watson and McCarthys' study 0.8% tumours (1) were intramuscular haemangioma .. The rate of correct diagnosis is only 8% to 19% in reported literature (2).Of the reported cases ,approximately 45% is located in the lower extremities (3).The disease occurs predominantly (90%) within first three decades (4) .Benign tumour making upto 0.8% (1,5,6) of haemangioma' were intramuscular haemangioma)and 8%of all benign tumours (6,7) .It is more common in the lower limb especially in the quadriceps (7) The etiology of intramuscular haemangioma is unknown or controversial trauma or congenital theories (3,8,9,10). Triceps muscle intramuscular haemangioma are uncommon that's why it is presented. Vascular malformation is often

confused with haemangioma.. Females are more common than male (1) Haemangioma are common in the skin, subcutaneous tissue followed by the deep tissue. Occasionally are intra articular synovial haemangioma may occur(12) and rarely in the bone, females are more than males(1,12). They are characterized by rapid endothelial growth .and 80% are located in head neck region. Rare in the extremity (13),especially in the upper extremity

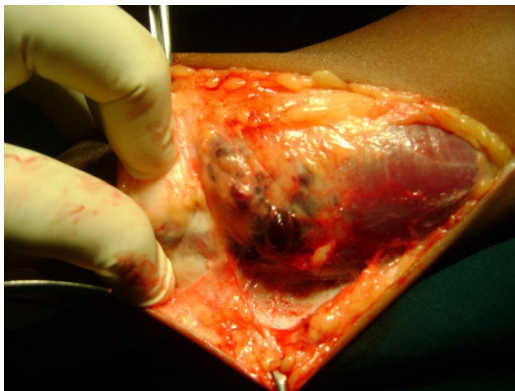
CASE REPORT :

A 14 years male presented with a diffuse swelling on his back of arm extending from tip of elbow to axilla measuring 6cm x 4cm x 3cm.No tethering of skin or skin involvement. The swelling is tender on movements of elbow joint. Doughy feeling .No thrill no bruit no reduction of swelling when the arm is raised above heart, no involvement of ulnar

nerve. Neurovascular examination was normal no palpable axillary lymph node. Range of motion of elbow Flexion/Extension 90 degree to 150 degree. Supination Pronation is normal no bony tenderness or no valgus or rotational disability. There is a vague history of trauma at the age of 6 year. Very it is increasing slowly increasing . Blood parameters are normal. X-rays showed (phlebolith) pearl like swellings around elbow in the vicinity of soft tissue swellings .FNAC guided by sonogram revealed Hematoma, CT Scan reports are as X-rays.Fig 1

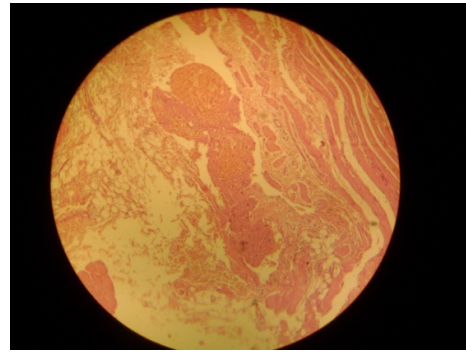
During operation :Under tourniquet and supraclavicular block

Per operatively it was revealed that Bloods are sprouting through intermuscular fibres of Triceps muscles(Fig -2) on the affected side, Pearl bits are coming out through muscle fibres No definite capsule is found no involvement of bone and capsule or periosteal or joint .Ulnar nerve is not involved in the lesions, soft tissue is removed for histopathology along with normal triceps muscle (12)



[Photograph 1]

[Histology : Photograph 2]



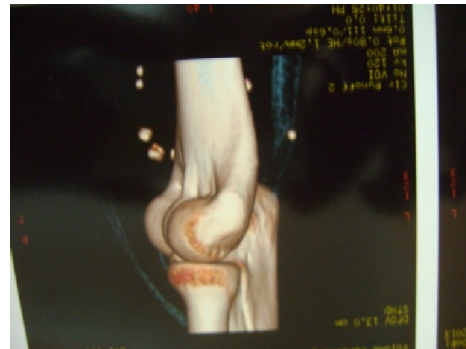Sections examined from the specimen shows dilated and communicating large thin walled blood vessels (many containing thrombus, focally calcified) interspersed with adipose tissue fibro collagenous tissue and skeletal muscles.

Histological features are suggestive of intramuscular haemangioma. No malignancy is reported.

DISCUSSION:

Intramuscular haemangioma are rare benign tumours making upto 0.8%of all haemangiomas (1,12),before age 30 years(4,12,); recurrence of intramuscular haemangioma is not uncommon due to incomplete excision of the lesion of the infiltrative growth pattern(12) Pain is the cardinal feature of presentation along with swelling. Lower limb is more affected than upper limb .Quadriceps is most frequently affected.(7)

Imaging strategies in the evaluation of soft tissue haemangioma



[Plain X-ray: Photograph 3]

Plain X-ray of intramuscular haemangioma shows soft tissue swelling shows soft tissue swelling and only 25%-30% of cases shows phlebolith(5,11). Periosteal reaction adjacent to haemangioma may mimic osteomyelitis or bone tumour(12). Periosteal reaction is not always seen.

CT Scan:

Ill defined mass of similar attenuation to muscle may be identified. Phlebolith if present may be seen.

MRI Scan:

Lobulated, and heterogeneous soft tissue mass with no features of local invasion. Phlebolith if present may be seen

Signal characteristics:

T1 overall signal is often intermediate to slightly high signal (relative to skeletal muscle)(14)

Some focal high signals may be present in a large proportion of lesions (upto 70%)

T2 high signal intensity tends to dominate T2 weighted images

Correlation of the findings of plain radiography, angiography, CT, MRI, Ultrasonography in 12 histologically proven cases of soft tissue haemangioma. By Adam Greenspan M D: Jhon Pet al in the Journal of Skeletal Radiology January 1992 Volume 21 issue 1 :- In 8 out of 9 intramuscular haemangioma plain radiograph demonstrated phleboliths suggested the diagnosis while 3 had normal radiograph. (in Springer Link). Angiogram showed pathognomonic features of soft tissue haemangioma in six patients which are deeply situated because of its invasiveness. MRI was characterised in all three patients. The lesion demonstrated intermediate signal intensity on T1 weighted spin echo images and extremely bright signal on T2 weighting. Ultrasonogram showed hypoechoic soft tissue mass in one case and mixed echo pattern in other. Doppler signal CT showed a

nonspecific mass in one of four cases and a mass with phlebolith in three."(15).

Patients with intramuscular haemangiomas may present with pain and swellings for years. The gross and microscopic appearance: capillary type is nonvascular and spongy whereas cavernous type is composed of large thin walled dilated vessels lined by flattened endothelial cells (6)

Histologically haemangiomas are classified based on the predominant type vascular channel as follows (11)

(1) Capillary haemangioma which are composed of small vessels lined by flattened endothelium. It is commonest type and subdivided into Juvenile, verrucosa's and senile type.

(2) Cavernous haemangioma: which are composed of dilated blood filled spaces, lined by flattened endothelium.

(4) Venous haemangioma which is composed of thick walled vessels containing muscles.

Intramuscular haemangioma may have 9% recurrences' rate(5) if incomplete surgical excision is done, but never metastasize or undergo malignant transformation. (5,12).

hamartomas' and malformations: Hamartomas' are result from an error in embryological development and are present at birth. In the case of vascular hamartomas and malformations they may become more obvious clinically sometime after birth as a consequence of progressive ectasies. The constituent vessels may be capillaries, veins, arteries, lymphatics, or a combinations of these vessels

Recent (Vascular malformations: Classification (16) Recent Hypotheses and Observations Regarding the Pathogenesis of haemangiomas :

Vasoproliferative tumours result from vasculogenesis (formations of primitive blood vessels from angioblast) rather than from

angiogenesis (The growth of vessels from pre-existing vessels)

within the anomaly that may originate from the placenta(18).

As previously thought By(17)Immature cells or progenitor stem/Progenitor cells are identified

[Comparison of Previous Terminology and New ISSVA(International Society for the study of Vascular Anomalies)]

Previous	ISSVA
Capillary or cavernous haemangioma of any organ(s)	Infantile haemangioma(s)
Infantile haemangioendothelioma(s)of the liver	Hepatic or infantile haemangioma(s)

Adult vertebral haemangioma	Venous malformations
Adult hepatic haemangioma	Venous malformation
Adult orbital cavernous haemangioma	Venous malformation

REFERANCES:

1. Watson WL, McCarthy WD (1940)Blood and lymph vessel tumour .A report of 1056 cases.SurgGyneolObset 71:569-588
2. Shallow Ta ,Egar Sa ,Wanger FB (1944)Primary haemangiomatus tumours of skeletal muscle AnnSurg 119 :700-7049 Pub Med)
3. Scott JES ,(1957) Haemangiomas in skeletal muscle .Br J Surg 44,496-501 (PubMed))
4. Shallow TA EgarSA,Wanger FB,(1944) Primary haemangiomatus tumour s of skeletal muscle Ann Surg119;700-704 9PubMed)
5. Allen PW,Enzingerangioma of skeletal muscle analysis of 89 caseses**Cancer 1972 ;29; 8 22,**
6. A T Wild ,Praab,RKrauspe; Skeletal haemangioma, Archive of orthopaedic and Trauma Surgery Februry 2000 VOLUME 120 Issue 3-4 pp139-143
7. Buetow Peter C ,Kransdorf Mark J,MosarRechardP,Jr ,Jelinek James S,and B Hudson Bery:Radiologic appearance of Intramuscular Haemangioma Emphasis on MR Imaging American Journal of radiology March 1990 0361 -803 /90/1543 -0563)
8. Trout HH, McAlister HA Giordano JM,Rich NM(1985) Vascular malformations Surgery97;36-41 (PubMed)
9. Ferguson I L C Haemangiomata of skeletal muscle.Br J Surg1972;59-8:634-637(PubMed)
10. Watson WL,McCarthyWD(1940)Blood And lymph vessels Tumour .A report of 1056 cases .SurgGyneolObstet 71 ;569-588)
11. Hein KD.,Mulliken J.B.,KozakewichH.P.,UptonJ.,BurrowsP.E.,Venous malformation of skeletal muscle Plast Reconstructive Surg 2002:110:1625-1635.(PubMed)
12. Patten D K Wani Z Kaminen S:Intramuscular cavernous haemangioma of the triceps ;Int J Surg case Rep: 2011. 2(6):86-89

13. Alejandra GuadalupeRanerojuraez, vector Manuel Rosales ,et al : International journal of dermatology (impact factor 1.18)09 2009 ,875-8 DOI 10 1111/J1365-4632.2008.04033 PubMed)
14. MemisA,ArkunR,UstunEe Magnetic imaging of intramuscular haemangiomawith emphasis oncontrast enhancement patterns.Clin Radiol.1996;51(3)198-204(PubMed citation)
15. Adam Greenspan M D.,Jhon P.,McGahan M D,PhilipVogelsang M D.,Robert M.,Szabo M D Imaging strategies in the evaluation of soft tissue haemangiomas of the extrimities:Corelation of the findings of plain radiography ,angiography,CT,MRI,and ultrasonography in 12 histologically proven caseses:Skeletal Radiology(1992)21, issue 1:11-18
16. Lisa H.LoweMD.,Tracy C.,Marchant, DO,,DouglasC.Rivard,DO and Amanda J ., Scherbel,BS ; - Vascular Malformations:Classification and Terminology the Radiologist needs to Know: ELSEVIER Seminars in Roentgen ology pp106-117
17. Cohen MM Jr :Vasculogenesis ,angiogenesis ,haemangiomas and vascular malformations Am J Med Gent 108: 265-274 ,2002
18. lo K MihmM,Fay A: Current theories on the pathogenesis of Infantile haemangioma. SeminOphthalmolol24 :172-177,2009

Date of submission: 23 December 2013

Date of Provisional acceptance: 08 January 2014

Date of Final acceptance: 12 February 2014

Date of Publication: 04 March 2014

Source of support: Nil; Conflict of Interest: Nil