

Case Report

Cutaneous sarcoidosis in an old post-surgical scar

¹Dr. Vikhyath P Raj, ² Dr. Kalpana Vineet, ³ Dr. Narayana V, ⁴Dr. Srija Koripalli

¹ MBBS, MS General Surgery - Junior Resident, Vydehi Institute of Medical Sciences and research Centre, Bengaluru.

² MBBS, MS General Surgery – Associate Professor, Vydehi Institute of Medical Sciences and research Centre, Bengaluru.

³ MBBS, MS General Surgery- Professor, Vydehi Institute of Medical Sciences and research Centre, Bengaluru.

⁴ MBBS, MS General Surgery - Junior Resident, Vydehi Institute of Medical Sciences and research Centre, Bengaluru.

Corresponding Author: Dr. Vikhyath P Raj



This work is licensed under a Creative Commons Attribution-NonCommercial 4.0 International License

Date of submission: 5 April 2023

Date of Final acceptance: 22 May 2023

Date of Publication: 02 June 2023

Source of support: Nil

Conflict of interest: Nil

Abstract:

Infiltration of pre-existing scars by sarcoidal granulomas is uncommon. The pathogenesis remains bizzare and the significance of this rather peculiar symptom remains neglected. Incidence of sarcoid specific cutaneous lesion with or without systemic involvement is 1.9/1 lakh population with female preponderance.

The case of a 48year old female with complaints of fever, myalgia and a painful surgical scar with a past history of open cholecystectomy two decades back is reported. Tissue biopsy after scar revision surgery revealed abundant non-caseating granulomas with asteroid bodies establishing a diagnosis of cutaneous sarcoidosis with an unremarkable systemic examination. Triamcinalone infiltration of the revised scar was performed with a consideration of short course of steroids at the earliest sign of inflammation/systemic involvement.

In the absence of systemic involvement, isolated cutaneous sarcoidosis could be an early sign of systemic progression which requires close monitoring and follow up.

Key-words: Cutaneous Sarcoidosis, Surgical scar.

Introduction:

Infiltration of pre-existing scars by sarcoidal granulomas is uncommon. Though the pathogenesis remains bizzare and significance of this rather peculiar symptom remains neglected.^[1] 3-4% of the patients have involvement of scars with or without systemic involvement i.e. 1.9/1 lakh population with a female preponderance. Post-surgical and post-traumatic scar are known to be most commonly involved.^[2]

Case History:

A 48year old female presented with complaints of dull aching, non-radiating pain localised to the previous scar of open cholecystectomy (20 years back). She also gave history low grade intermittent fever of 3 episodes over the past month associated with myalgia. She is a known diabetic on regular medications

Per abdomen examination revealed a 6x0.5cm right subcostal scar which was hypertrophied with scar tenderness and local rise of temperature. Rest of the systemic examination was unremarkable.

Ultrasound abdomen and pelvis was suggestive of a 1-4cc collection in the lateral end of the scar. Pre-operative routine blood investigations were within normal limits and a chest radiograph showing normal lung fields. She underwent exploration under GA; intraoperatively no foreign body or collection noted hence proceeded with scar revision surgery.

Histopathological examination revealed abundant confluent, non-necrotising non-caseating granulomas in the dermis. Few multinucleated giant cells displayed asteroid bodies substantiating a diagnosis of cutaneous sarcoidosis with no evidence foreign bodies or atypical cells.

Head to toe re-examination showed no signs of systemic involvement with normal Vitamin D3 and calcium levels on further investigation.

Triamcinalone infiltration of the revised scar was performed in an attempt to prevent recurrent inflammation. A 6 month follow up showed a healthy surgical scar healed by primary intention with no sign of local inflammation or tenderness.

Yearly follow up was advised for periodic assessment and early detection and prompt treatment of systemic sarcoidosis.

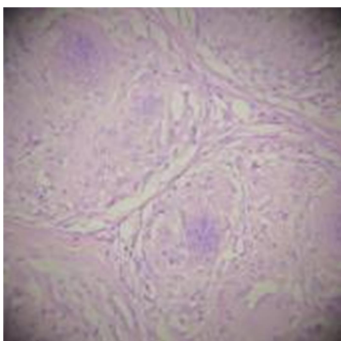


Figure 1 – Confluent granulomas

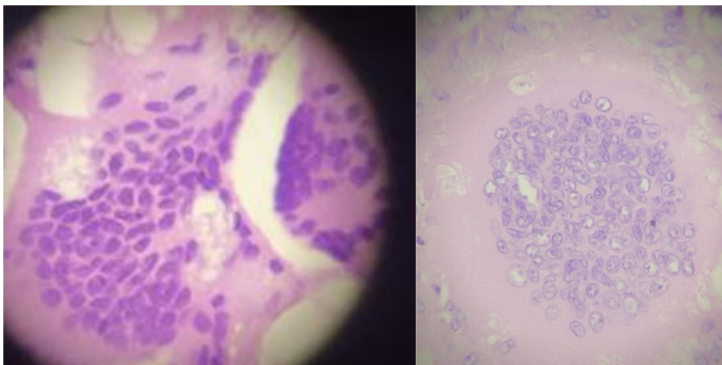


Figure 2 and 3 – Giant cells with asteroid bodies

Discussion:

Systemic sarcoidosis India has an incidence of 10/1000 population. In majority of the cases, patients present with pulmonary manifestations with a cutaneous involvement in ~20-40% of cases. Skin manifestations are categorised into specific and non-specific skin lesions.^[3] The majority of patients present with maculopapular eruption, lupus pernio, subcutaneous nodules, and erythema nodosum.^[4] Isolated scar sarcoidosis is a sarcoid specific skin lesion with an incidence of 2.9-5.4%. It has been reported at sites of previous infection, tattoos, lupus pernio, venepuncture sites, beside the traumatic and surgical scars.

Isolated cutaneous sarcoidosis represent a benign variant which may progress to systemic sarcoid. A study done previously reported that 30% of patients with isolated cutaneous lesions developed systemic features of involvement after a period of 1 month to 1 year.^[5] In patients post treatment of systemic sarcoidosis reactivation of scars can signify recurrence/ relapse. The differentials that can be considered are Mycobacterium infections, hypertrophic scar, foreign body, keloids and granulomatous diseases. Several studies have hypothesized that macrophages on phagocytosed foreign bodies may cause the release of Acetylcholine esterases and lymphokines, which lead to the development of granulomas.^[6] The treatment and prognosis of cutaneous sarcoidosis is primarily dependent on the degree of systemic involvement. Topical steroid therapy may be sometimes effective for purely cutaneous sarcoidosis.^[7] In conclusion, a highly suspicious scar, traumatic or surgical with recent onset of localised symptoms has to be evaluated for scar sarcoidosis and if confirmed, the patient has to be periodically monitored for systemic progression^[8] with a short course of systemic or local steroids at the earliest sign of cutaneous or systemic involvement.

References:

1. Muralidhar S, Handa S, Sharma VK, et al. Scar sarcoidosis-sparing post surgical scar. *Indian Journal of Dermatology Venereology and Leprology* 1999;65:279-80.
2. Sorabjee JS, Garje R. Reactivation of old scars: inevitably sarcoid. *Postgrad Med J*. 2005 Jan;81(951):60-1.
3. Sreeja C, Priyadarshini A, Premika, Nachiammai N. Sarcoidosis - A review article. *J Oral Maxillofac Pathol*. 2022 Apr-Jun;26(2):242-253.
4. Milman N, Hoffmann AL, Byg KE. Sarcoidosis in children: epidemiology in Danes, clinical features, diagnosis, treatment and prognosis. *Acta Paediatr*. 1998;87:871-878.
5. Kocak C, Yucel E, Namdar ND, Tak H. A case of scar sarcoidosis developing in an old scar area on the forehead. *Acta Dermatovenerol Alp Pannonica Adriat*. 2015;24(3):61-3.
6. Kwon SH, Jeong K muk, Baek YS, Jeon J. Linear scar sarcoidosis on blepharoplasty line mimicking a hypertrophic scar: A case report. *SAGE Open Medical Case Reports*. 2018;6.
7. English JC, 3rd, Patel PJ, Greer KE. Sarcoidosis. *J Am Acad Dermatol*. 2001;44:725-743.
8. Hong YC, Na DJ, Han SH, Lee YD, Cho YS, Han MS. A case of scar sarcoidosis. *Korean J Intern Med*. 2008 Dec;23(4):213-5.