

Original article:

Ultrasonographically guided fine needle aspiration cytology of breast

Sagale MS , Jadhav MV

Department of Pathology, B.J. Medical College, Pune, Maharashtra, India – 411001

Corresponding author : Dr. Mangesh Sagale

Abstract:

Introduction: The incidence of cancer breast is on rise and its early detection is warranted. Inclusion of USG guided FNAC in Tripletest instead of mammography will be cost effective way of early detection of breast cancer.

Methodology : 75 breast lesion from 69 female and one male were evaluated with clinical examination, USG images and USG guided FNAC. Twenty cases were further subjected to histopathological diagnosis. The USG findings and USG guided FNAC was correlated with histopathological or comprehensive diagnosis with Tripletest (Clinical findings, USG imaging and USG guided FNAC) .The data was analysed applying statistical test for diagnostic accuracy.

Observations & conclusion: The sampling adequacy of USG guided FNAC was 90.6%. The diagnostic accuracy, sensitivity, specificity, positive predictive value and negative predictive value of USG and USG guided FNAC was 96, 94.66, 94.73, 89.43, 96.42, 96.42, 90, 100,96.10, 96.10, respectively.

Inclusion of USG guided FNAC in Tripletest emerged as an useful tool in diagnosis of breast lesion.

Keywords: Ultrasonography, FNAC

INTRODUCTION

According to population based cancer registries 2009-2011, breast was the commonest leading site for cancer with incidence of 31.3 (Age adjusted incidence of 23.3). Moreover, cancer breast was more common in the younger age group of 25-50 years. In this context need of the hour is breast awareness, regular screening, detection and treatment of cancer breast in earlier stage. FNAC guided by USG can be of great value in this matter. USG guided FNAC claimed to be valuable and reliable technique in diagnosis of nonpalpable lesions ¹ though is best suited and indicated for nonpalpable lesion, even today in a developing country like India , woman approach health care system for cancer breast when it becomes palpable. In this view, we have studied an approach of diagnosing breast lumps with triple

approach of clinical examination, USG and USG guided FNAC of the lesion during 2002 through 2003. Such an approach is an ultra modification of original Tripletest which consists of assessing breast lesion with clinical examination of lump, mammography and FNAC. Sundresh et al have tried a modification of this test with clinical examination of lump, USG and FNAC.² In present scenario of alarmingly rising incidence of cancer breast, we found it worthwhile to share our experience in this matter. This background will prepare us to extent our expertise and experience for nonpalpable lesion.

MATERIAL AND METHODS

Present study was done on prospectively registered patients during 2002 through 2003 in Sassoon General Hospitals Pune. Sample size was estimated with the help of expert from our college using online

sample size calculator. The study was approved by research authority. After taking informed consent, 70 patients with breast symptoms, attending outdoor as well as indoor departments of the hospital were enrolled for the study. Clinical history of symptoms related to the breast such as mastagia/lumpy feel/nipple discharge, retraction, generalized breast discomfort and its relation with menstruation was noted. Breast was examined for lump with special reference to site, size, tenderness, mobility, consistency and fixation to underlying chest wall. Ultrasonographic examination of breast was done with machine Ecocoe diagnostic, Ultrasound system Model SSA-340A with hand held microtransducer of center frequency 7 MHZ. The ultrasonographic examination was carried with special reference to site, size, echogenicity, heterogenicity, margins, parenchymal interface of the breast lesion and presence or absence of microcalcification. The final impression was noted. It was based on USG findings correlated with clinical findings noted by surgeon, cytopathologist and radiologist. This was followed by US guided FNAC.

Ultrasonographically guided FNAC was done by free hand technique and without local anaesthesia.. The needle was inserted with oblique pass until tip of the needle was visualized within mass and aspiration was done. Samples were obtained. Number of passes were noted. The cystic lesions were aspirated till they

collapsed and reduced in size. Aspirated material was expressed at least on two previously numbered glass slides and thin smears were prepared with the help of 0.4mm thickness coverslip. The smears were air dried and stained with Leishman's stain and Haematoxylin and Eosin stain. Evaluation of cytology was done with special reference to adequacy of sampling and nature of cellular yield. The diagnosis was offered independently and purely on cytological criteria without referring to USG or palpation findings.

The cases were scored for Tripletest depending upon the clinical examination, USG findings and cytological findings . Fixed lump, irregular parenchymal interface and malignant or suspicious cytology was scored for one point each and the scores were added for final score.² We considered this as Ultra modern Tripletest . Final diagnosis of breast lesion was offered comprehensively and on critical evaluation of clinical, USG , cytological and whenever available histological findings. Whenever histological studies were available, histological findings decided the final diagnosis. Correlation of USG diagnosis and cytological diagnosis was done with final diagnosis and data was analyzed to find out utility parameters of both these procedures. For calculating utility parameters of these procedures Fornage formula was used which considered inadequate samples from malignant cases as false-negative & inadequate samples from benign cases as false-positive.⁴

Medworld-asia

Dedicated for quality Research Publications

OBSERVATIONS:

Table I: Clinical characterization of patients with breast lesions:

	Clinical characteristics	Number
A	Sex distribution:	
	Female	69
	Male	01
B	Age distribution: (Range: 10 – 75 years)	
	Premenopausal	58
	Postmenopausal	11
C	Number of lesions	
	Unilateral	70
	Bilateral	05

Experience with Technique: Supine position was convenient for aspirating and visualizing larger lesions while smaller lesions, less than 2cm in diameter needed sitting position with hand above head. Needle visualization and aspiration was optimum with oblique pass. Malignant lesions of hard consistency offered resistance & delayed visualization of needle and posed difficulty in aspiration. Cystic lesions were most easy to visualize and aspirate. Detection of microcalcification was possible in 3 cases, but could not be confirmed on cytology.

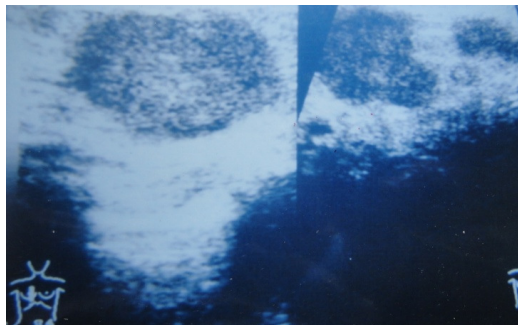


Fig. No.1USG,Breast carcinoma seen as solid, hypoechoic , heterogenous nodule with irregular borders.

Pain and tenderness was seen in 2 cases of abscess, but was not evident in cases of mastalgia. Procedure was well tolerated, and did not demand local anaesthesia. No complication was noted. Simple cyst could be aspirated completely, which collapsed and disappeared.

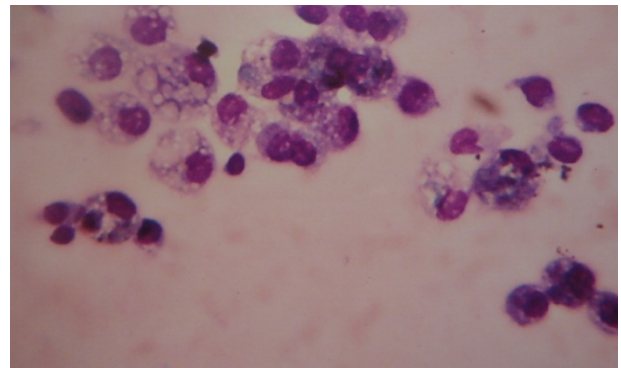


Fig. No.2 Photomicrograph. Cytology of simple cyst showing numerous cyst macrophages. Leishman stain X400.

Difference of size of lesion on palpation and USG was statistically significant with size being bigger roughly by 1cm on palpation than on USG ($p < 0.05$).

Sampling Adequacy: It was 90.6%. Fifty-six adequate aspirates were obtained at first pass, 12

needed 2 passes, and 7 yielded acellular aspirates despite 3 passes. These included 4 aspirates from

normal breast confirmed on USG and one case each of fibrocystic disease, simple cyst & malignancy.

Table II Correlation of Final Diagnosis with USG and Cytological Diagnosis:

	Final Diagnosis based on Ultra modified Triplettest**/Histopathology	USG Diagnosis	Cytological Diagnosis
1	Abscess (02)	02	02
2	Fat Necrosis (01)	01	01
3	Simple cyst (07)	07	06*
4	Fibrocystic disease (08)	07	07*
5	Gynaecomastia (01)	01	01
6	Mastitis (02)	02	02
7	Intramammary LN (01)	01	01
8	Fibroadenoma (27)	27	28
9	Giant fibroadenoma (01)	01	01
10	Phyllodes tumour (02)	02	02
11	Carcinoma-Breast (19)	20	17*
12	Normal Breast	04	04
		75	72

* One case each in these groups showed acellular smear.

** Breast lesion assessment based on clinical examination with USG and USG guided FNAC

On USG, 2 cases were over-diagnosed as malignancy, one of which was fibrocystic disease with epitheliosis and showed a 1.7 x 1.2 cm lump with irregular speculated margins on USG; and another was fibroadenoma with 2.3 x 1.6 cm sized lump with diffuse margins & irregular parenchymal interface. Both these were reported as suspicious of malignancy and cyto-histological correlation was advised. Thus, USG findings of diffuse or speculated margins or irregular parenchymal interface were over-rated. One case of malignancy was under-

diagnosed as benign on USG with a hypochoieic, homogenous lump with diffuse outline and size of 1.0 x 0.8 cm.

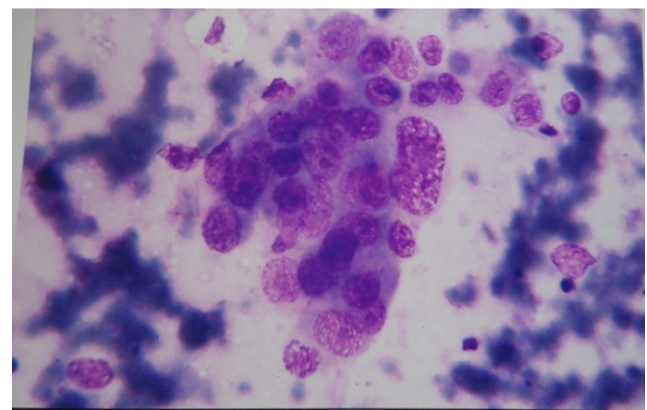


Fig No: 3 Photomicrograph. Cytology of malignant breast showingloosely cohesive ductual epithelial

cells with pleomorphic ,hyperchromatic nuclei with prominent nucleoli. Leishman stain X400.

On Ultra modern Tripletest , all benign lesion except one case of fat necrosis (score 1) scored zero. One case of histologically proven carcinoma breast had score of 2 because of acellular aspiration.

Table III: Diagnostic failure on USG and FNAC:

Diagnostic failure	USG (n)	USG-guided FNAC (n)
False-positive	02	00
False-negative	01	01
Inadequate malignant sample	-	01
Inadequate benign sample	-	02
Total	03	04

Table IV: Evaluation of utility of USG-guided FNAC and USG:

	USG guided FNAC	USG
Sensitivity	89.43%	94.73%
Specificity	96.42%	96.42%
Positive predictive value (PPV)	100.00%	90.00%
Negative predictive value (NPV)	96.10%	96.10%
Diagnostic accuracy	94.66%	96.00%

Comparison with Blind FNAC (for cellular yield):

Total number of blind FNACs performed by clinicians and referred to us for cytological evaluation during the study period was 328. Of these 131 were inconclusive, due to inadequate cellular yield even on multiple passes. USG-guided FNAC

with 96% sampling adequacy is far more superior to blind FNAC.

DISCUSSION:

With state of art technology currently available, USG-imaging of breast can not only differentiate cystic from solid lesions, but also further characterize them as benign or malignant. Moreover, because of improved spatial resolution and real-time imaging capability it has emerged as the optimal guidance technique for palpable breast lumps and non-palpable sub-clinical lesions. The distinct advantage of USG-guided FNAC is full real-time monitoring of needle-tip during insertion and aspiration and multidirectional sampling which increases yield of aspiration and decreases chances of inadequate samples. The procedure is rapid, and is able to visualize even superficial & peripheral lesions not accessible to mammogram. It surpasses USG-guided core biopsy owing to its pinpoint accuracy in aspiration, rapidity, and excellent tolerance by patient, safety, and cost-effectiveness.^{4,5,6}

Sassoon General Hospitals Pune caters for patients from lower socio-economic and educational strata with no awareness for non-palpable lesions. The facilities for mammography screening were not available when this study was carried out. This resulted in inclusion of very few non-palpable lesions in our study. Incidentally these nonpalpable lesions were nonspecific pathology like mastalgia or lumpy breast and on USG and cytology turned out be no lesions. We have not insisted on histological confirmation in every case included in study. This did not hinder us in deciding the final diagnosis, which was based on critical clinico-sonographic and cytological correlation which we consider to be Ultra-modified Tripletest for assessment of breast lesion.² Insistence on histological confirmation in

every case would have defied the very purpose of guided FNAC. Esserman L J in his invited comment on work done by Hatada et al had expressed the similar views.⁶ However, the finding of misdiagnosed cases on USG & FNAC in present study emphasize the need of re-evaluation of patients and histological study even on single suspicious finding on clinical, USG, or cytological finding.

USG-guided FNAC had supreme positive predictive value of 100% and comparable specificity as that of USG. Its sensitivity was compromised on account of one missed case of malignancy and one inadequate sample from histologically diagnosed case of malignancy. Specificity of USG-guided FNAC remains comparable to USG in spite of there being no false-positive result in cytology (in contrast to 2 false-positive cases on USG). This compromised specificity was due to inadequate samples from benign cases, which had to be considered as misdiagnosed cases. Utility of USG-guided FNAC in the present study is comparable to other workers⁶.⁹With these findings in the present study, we foresee a great future for USG-guided FNAC in diagnosing the breast lesions. Advantage of USG in assessment of breast lesion need not be overemphasized. It plays a role in differentiating cystic from solid masses, in evaluating palpable breast masses which are not radiologically dense breast and young, pregnant and

lactating females susceptible to radiation damage. Furthermore USG can confirm malignancy that is otherwise invisible on mammography due to radiologically dense breast. USG is presently not considered as screening test. But in view of its added sensitivity to detect dense breast lesions, it has a great future in this matter¹⁰

USG guided FNAC is a simple, well tolerated, low cost, rapid, safe procedure without any side effect or serious after effect. Recently it is also used for grading the malignant lesions and thereby detecting biological characteristics of cancer breast. It is also possible to subject the cytological smears to immunochemical stains. Pagani et al have aptly remarked that such a procedure has twofold advantages. On one hand it provides a means of preoperative, biological characterization of an operable cancer breast and immunochemical characterization of lesions in patients who need medical management. One added advantage of USG guided FNAC procedure is ability to sample axillary lymph nodes for presence of metastasis. For best results it is advisable that surgeon, radiologist and cytologist collaborate closely and work as a team.¹¹

Acknowledgment:

Late Dr. Getanjali Vaidya, Department of Radiology , B. J. Medical Collge and Sassoon hospital Pune.

REFERENCES:

1. Klijanienko j, Cote JF, Thibault F Zafrani B et al: Ultrasound guided fine needle aspiration cytology of nonpalpable breast lesions: Institut Curiers experience with 1998; 84(1): 36-41
2. Sundresh N, Narendran S, Ramanathan M. MODIFIED TRIPLE ASSESMENT IN BREAST LUMPS .International Journal of Pharmacology & Toxicology / 2(2), 2012 ; 2249- 7676:67-9.
3. Ghimire B, khan MI, Bibhusal T, Singh Y, Sayami P. : Accuracy of triple test score in the diagnosis of palpable breast lump. JNMA J Nepal Med Assoc. 2008 Oct-Dec;47(172):189-92

4. Kline Fornage BD: Guided needle biopsy of non-palpable breast lesions. Calculation of accuracy values. *Radiology* 1990; 177: 884-5.
5. Fornage BD: Sonographically guided needle biopsy of non-palpable breast lesions. *J Clin Ultrasound* 1999; 27(7): 385-98.
6. Hatada T, Aoki I, Okada K, Nakai T, Utsunomiya J: Usefulness of ultrasound-guided fine needle aspiration biopsy for palpable breast lesions. *Arch Surg* 1996;131:1095-8.
7. Gordon PB, Goldenberg SL, Chan NHL: Solid breast lesions: Diagnosis with US-guided fine needle aspiration biopsy. *Radiology* 1993; 189: 573-80.
8. Zardawi IM, Hearnden F, Mayer P, Trevan B: Ultrasound guided fine needle aspiration cytology of impalpable breast lesions in rural setting. *Acta Cytol* 1999; 43: 163-8.
9. Gordon PB, Goldenberg SL, Chan NHL: Solid breast lesions: Diagnosis with US-guided fine needle aspiration biopsy. *Radiology* 1993; 189: 573-80.
10. Sachin Prasad N, Dana HouserKova.: A comparison of Mammography and Ultrasonography in the evaluation of breast masses. *Biomed Papn Med Fac Univ Palacky Olomouc Czeck Repub.* 2007, 151(2) 315-322.
11. C. Pagani , D. R. Coscia, Dellabianca, M. Bonardi, S. Alessi, and F. Calliada.: Ultrasound guided fine-needle aspiration cytology of breast lesions. *J Ultrasound.* 2011 December; 14(4): 182-187.

Date of submission: 18 January 2014

Date of Provisional acceptance: 22 February 2014

Date of Final acceptance: 27 February 2014

Date of Publication: 07 March 2014

Source of support: Nil; Conflict of Interest: Nil