

## Original article:

# Study of thyroid lesions using ultrasonography

<sup>1</sup>Dr Kiran Naiknaware , <sup>2</sup>Dr Ibrahim Ansari , <sup>3</sup>Dr Shweta Shendey\*

<sup>1</sup>Associate Professor, DY Patil Medical College, Pune

<sup>2</sup>Associate Professor, B.J.Government Medical College, Pune

<sup>3</sup>Assistant Professor B.J.Government Medical College, Pune

Corresponding author\*

## Abstract

**Introduction:** Thyroid nodularity is very common in clinical practice. In a population study, clinically apparent thyroid nodules were found in 6.4 percent of women and 1.5 percent of men .Thyroid nodules occur in up to 50% of the normal adult population and most of them are not detectable by physical examination.

**Methodology:** This was Prospective observational study conducted over two years duration. The study population included all of the suspected cases of thyroid lesions admitted at a tertiary care center and referred to Radiodiagnosis department with sample size as 60.

**Results :** It was observed that among 55 patients of thyroid swelling most of the patients had swelling with soft consistency i.e.23 cases (41.81%), followed by nodular consistency in 13 cases (23.63%), solid in 12 cases (21.81%) Hard consistency in 4 cases and firm in 3 cases (5.45%). In our study, after performing USG, in maximum number of cases lesion was found in both lobes/diffuse i.e., 26 (43.3%) followed by right lobe and left lobe i.e. 17 (28.3%) and 13 (21.66%) respectively. Only 2 (3.33%) lesions were found in isthmus. No sonographically detectable lesion was seen in 2 cases (3.33%)

**Conclusion:** Ultrasound helps to characterize the lesion morphology, echotexture and extent of the disease. It helps to know whether the lesion is solitary or multiple. It helps to differentiate between solid and cystic lesions. In most of the cases ultrasound helps to differentiate benign lesions from malignant thyroid lesions.

**Keywords:** Thyroid lesions , ultrasonography , thyroid nodule

## Introduction:

Thyroid nodularity is very common in clinical practice. In a population study, clinically apparent thyroid nodules were found in 6.4 percent of women and 1.5 percent of men [1].Thyroid nodules occur in up to 50% of the normal adult population and most of them are not detectable by physical examination [2].However, only 7% of the thyroid nodules are malignant and it is critical that they are accurately identified [3] Palpable nodules occur only in 4% to 7% of the population. Small nodules of 2 mm size can be detected by high-resolution ultrasonography which can be missed by physical examination [4].Most of these nodules are benign and on further evaluation, approximately 2% to 12% of them were found to represent malignancy [5,6].The prevalence of thyroid enlargement is about 3%-8% in the general population and is greater than 50% after age of 65 years [7,8] The prevalence increases to 19– 27% on including enlargements found on ultrasonography [9 ].

### Methodology:

This was Prospective observational study conducted over two years duration. The study population included all of the suspected cases of thyroid lesions admitted at a tertiary care center and referred to Radiodiagnosis department with sample size as 60.

#### Inclusion criteria:

- 01) Patients presenting with clinically palpable swelling in the neck region.
- 02) Patients presenting with congenital abnormalities of thyroid gland.
- 03) Patients with clinical suspicion of thyroid dysfunction.
- 04) Patients complaining of pain in thyroid region.

#### Exclusion criteria:

- 01) All patients not giving consent for histopathological examinations.
- 02) Secondaries in the neck.
- 03) Swelling in the neck other than thyroid.
- 04) Ectopic thyroid
- 05) Post-operative recurrences.
- 06) Post-radiotherapy and post radio isotopic therapy of thyroid.
- 07) All patients with bleeding diathesis.

The observation findings in 60 patients have been analyzed. These cases were referred to the department of Radiodiagnosis for ultrasonography.

### Results

**Table no: 1 Distribution of cases according to site of swelling**

Site of Swelling	No. of Cases	Percentage
Left Side	05	8.33%
Right Side	13	21.6%
Mid Line/Diffuse	15	25%
Both Sides	22	36.6%
Total Swellings	55	91.67%
No Swelling	5	8.33%
Total	60	100%

The above table shows maximum cases swelling was observed on both sides/Diffuse 22 (36.6%) followed by midline 15 (25%) and right side 13 (21.6%). Lowest swelling sites observed on left side 5 (8.33%).

**Table no: 2 Distribution of cases according to duration of swelling**

<b>Duration</b>	<b>No. of Cases</b>	<b>Percentage</b>
<b>0 – 6 Months</b>	<b>21</b>	<b>38.18</b>
<b>7 months – 1 Year</b>	<b>23</b>	<b>41.81</b>
<b>1.1 – 2 Years</b>	<b>10</b>	<b>18.18</b>
<b>&gt; 2 Years</b>	<b>01</b>	<b>1.81</b>
<b>Total</b>	<b>55</b>	<b>100</b>

The above table shows maximum time duration for which patients had swelling at presentation was 7 months to 1 year duration i.e. 23 (41.81%) followed by 21 cases in 0-6 months duration, 10 cases had a history of 1.1- 2 years duration and more than 2 years duration of swelling was found in 1 case.

**Table no: 3 Distribution of cases according to clinical examination of Consistency of Thyroid Swelling**

<b>Consistency</b>	<b>No. of Cases</b>	<b>Percentage</b>
<b>Soft</b>	<b>23</b>	<b>41.81%</b>
<b>Solid</b>	<b>12</b>	<b>21.81%</b>
<b>Nodular</b>	<b>13</b>	<b>23.63%</b>
<b>Firm</b>	<b>03</b>	<b>5.45%</b>
<b>Hard</b>	<b>04</b>	<b>7.27%</b>
<b>Total</b>	<b>55</b>	<b>55 (100%)</b>

It was observed that among 55 patients of thyroid swelling most common consistency was found to be soft i.e., 23 (41.81%), followed by nodular 13 (23.63%), solid 12 (21.81%), hard in 4 (7.27%) cases and firm in 3 cases (5.45%).

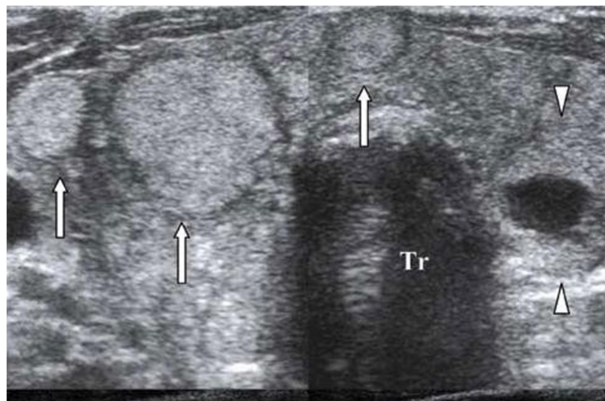
**Table no: 4 Distribution of cases according to site of lesion onultrasound**

Lesion	No. of Cases	Percentage
Left Lobe	13	21.6%
Right Lobe	17	28.3%
Both Lobe	26	43.3%
Isthmus	02	3.33%
No lesion found	02	3.33%
<b>Total</b>	<b>60</b>	<b>100</b>

The above table shows, on ultrasound examination maximum number of cases lesion was found in both lobes i.e., 26 (43.3%) followedby right lobe and left lobe 17 (28.3%) and 13 (21.66%) respectively. Only2 (3.33%) lesions were found in isthmus. No lesion was detected in 2 cases (3.33%).

A total of 60 patients with various thyroid disorders formed the study sampleinvestigated by ultrasonography.

**Fig : A 37 yrs old female with complains of swelling over neck region with increasedsensitivity to heat, weight loss and palptations**



**Discussion:**

In our study majority of cases found in the age group of 40-49 years e.g 16 (26.66%) followed by 12(20%) cases in 30-39 yrs age group,11(18.33%) in 50-59 yrs age gorup,7cases in 60-69 years age group,6 (10%) cases in 20-29age group, 5(8.33%) cases in 70-79 age group and 3(5%) cases were found in 10-19 group.

In our study, majority of study participants were females 41 (68.33%) and males were 19 (31.67%). Female to male ratio was 2.2:1 Female to male ratio of 4.7:1 was reported. Mary C. Frales et al[ 10] studied 1985 patients of which 1742 occurred in womenand 203 were males proving female predominance. Majority of female cases found in the age group of 40-49 yrs e.g 11, followedby 8 cases in 50-59 yrs, 7 in 30-39 yrs,6 in 60-69 yrs, 4 in 20-29 yrs and 70-

79 yrs and 1 case found in 10-19 yrs age group. Most male cases i.e 5 cases were found in 30-39 yrs and 40-49 yrs age group, 3 in 50-59 yrs, 2 in 20-29 yrs, 1 in 10-19 yrs, 60-69 yrs and 70-79 yrs each.

Similar results reported by Jeffery R. Wienke et al [11] with an age range of 20 – 60 years, in patients with thyroid nodules – most of the patients were in the age group of 3<sup>rd</sup> to 5<sup>th</sup> decade and out of 68 cases 63 were females and 7 were males. In our study, clinically in maximum cases swelling was observed on both sides i.e. 22 (36.6%) followed by midline in 15 cases (25%) and right side in 13 cases (2%). Lowest no of swelling were observed on left side in 5 cases (8.33%). No swelling was found in 5 patients clinically. Similar results were reported by Monika Chaudhary et al, who found out that diffuse neck swelling was present in majority of cases i.e 36% of patients, followed by 17% on right side and 30 % on left side [12].

In our study, maximum time duration for which patient had history of swelling was 7 months to 1 year duration i.e., 23 cases (41.81%) followed by 21 cases (38.8%) in 0-6 months duration, 10 cases (18.18%) had a history of 1.1- 2 years duration and more than 2 years duration history was found in 1 case (1.8). Similar result reported by Monika Chaudhary et al [94] who found out that most of the patients (60%) had swelling for duration of less than 1 year, 26 % patients had swelling for 1-3 yrs and 14% patients had swelling for 5-10 yrs.

It was observed that among 55 patients of thyroid swelling most of the patients had swelling with soft consistency i.e. 23 cases (41.81%), followed by nodular consistency in 13 cases (23.63%), solid in 12 cases (21.81%) Hard consistency in 4 cases and firm in 3 cases (5.45%). In our study, after performing USG, in maximum number of cases lesion was found in both lobes/diffuse i.e., 26 (43.3%) followed by right lobe and left lobe i.e. 17 (28.3%) and 13 (21.66%) respectively. Only 2 (3.33%) lesions were found in isthmus. No sonographically detectable lesion was seen in 2 cases (3.33%)

#### **Conclusion:**

Ultrasound helps to characterize the lesion morphology, echotexture and extent of the disease. It helps to know whether the lesion is solitary or multiple. It helps to differentiate between solid and cystic lesions. In most of the cases ultrasound helps to differentiate benign lesions from malignant thyroid lesions.

#### **References:**

1. J. B. Vander, E. A. Gaston, and T. R. Dawber, "The significance of nontoxic thyroid nodules: final report of a 15 -year study of the incidence of thyroid malignancy," *Annals of Internal Medicine*, vol. 69, no. 3, pp. 537–540, 1968.
2. Popli MB, Rastogi A, Bhalla P, Solanki Y. Utility of gray -scale ultrasound to [1]differentiate benign from malignant thyroid nodules. *Indian J Radiol Imaging*. 2012;22(1):63-68.
3. Papini E, Guglielmi R, Bianchini A, Crescenzi A, Taccogna S, Nardi F, et al. Risk [2]of malignancy in nonpalpable thyroid nodules: predictive value of ultrasound and color-Doppler features. *J Clin Endocrinol Metab*. 2002;87(5):1941-46.
4. Bruneton JN, Balu-Maestro C, Marcy PY, Melia P, Mourou MY. Very high frequency [3](13 MHz) ultrasonographic examination of the normal neck: detection of normal lymph nodes and thyroid nodules. *J Ultrasound Med*. 1994;13(2):87-90.
5. Brander AE, Viikinkoski VP, Nickels JI, Kivisaari LM. Importance of thyroid abnormalities detected at US screening: a 5 -year follow-up. *Radiology*. 2000;215(3):801-06.
6. Palaniappan MK, Aiyappan SK, Ranga U. Role of gray scale, color Doppler and spectral Doppler in differentiation between malignant and benign thyroid nodules. *Journal of clinical and diagnostic research: JCDR*. 2016 Aug;10(8):TC01.

7. Wiest PW, Hartshorne MF , Inskip PD, Linda A,Crooks. Thyroid palpation versus high-resolution thyroid ultrasonography in the detection of nodules. *J Ultrasound Med.* 1998;17:487-96.
8. Morstensen JD, Woolner LB, Bennett WA. Gross and microscopic findings in clinically normal thyroid glands. *J Clin Endocrinal Metab.*1955;15:1270-80.
9. Carroll BA. Asymptomatic thyroid nodules: incidental sonographic detection. *Am J Roentgenol.*1982;138(3):499-501
10. Mary C. Frates, Carol B. Benson et al. Prevalence and distribution of carcinoma in patients with solitary and multiple thyroid nodules on sonography. *The Journal of Clinical Endocrinology and Metabolism.* 2006; 91 (9): 3411-3417.
11. Jeffery R Wienke MD., Wuikchong MD., et al. Sonographic features of benign thyroid nodules. In observer reliability and overlap well malignancy.
12. Monika Chaudhary, Nitish Baisakhiya, Gurchand Singh *Indian J Otolaryngol Head Neck Surg.* 2019 Oct; 71(Suppl 1): 893– 904. Published online 2019 Feb 8. doi: 10.1007/s12070-019-01616